

A Placental Cyst Behind the Fetal Neck in the Mid-trimester Prenatal Sonography May Mimic a Fetal Cystic Hygroma

CME Credits

Ching-Yu Chou*, Li-Chan Lin

Department of Obstetrics and Gynecology, Cathay General Hospital, Shinchu Branch, Shinchu, Taiwan

Dear Editor,

Subchorionic placental cysts occur in up to 5% of pregnancies, and the etiology is still controversial. Small single subchorionic placental cysts are of no clinical importance and no obstetrical management should be altered. However, a placental cyst beside the fetal neck in the mid-trimester prenatal sonography may mimic a fetal cystic hygroma that was poor prognosis. We reported a case of a placental cyst behind the fetal neck posteriorly in the mid-trimester prenatal sonography. A cyst-like lesion measured about 42 mm behind the fetal neck was detected by ultrasonography [Figure 1a]. This placental cyst was mistaken as a fetal cystic hygroma at first. However, further well examination confirmed the diagnosis of a placental cyst. At 34 gestational weeks of prenatal examination, an ultrasound revealed normal fetal growth with an intact fetal neural tube, and an independent placenta cyst was detected by transabdominal ultrasonography examination. The cyst was approximately 75 mm × 65 mm in diameter, and the intracystic echolucent area had an echodensity equivalent to that of amniotic fluid [Figure 1b and c]. Blood flow was not detected in the cystic structure on color Doppler ultrasound, and the Doppler examination of the umbilical artery revealed normal velocity and pulsatility. At 38 weeks of gestation, the woman came to our delivery room due to the onset of labor, then, a live mature female baby was delivered through vertex position through the vagina, weighting 3180 gm, body length 47 cm, with Apgar score of 9 and 9 at 1 and 5 min, respectively. A placenta cyst measured about 5cm was noted and revealed as subchorionic cyst with extravillous trophoblast cells found within the lining of the inside of the cystic wall [Figure 1d].

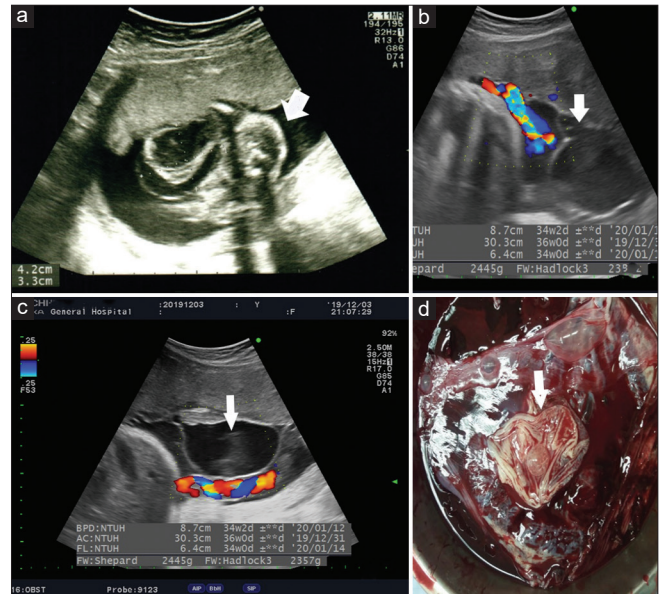


Figure 1: At the 19th week, a cyst-like lesion measured about 42 mm behind the fetal neck (arrow) (a). At 34 gestational weeks, an ultrasound revealed an independent placenta cyst measured 75 mm × 65 mm in diameter (arrow) (b and c). After delivery, a placenta cyst (arrow) was noted (d)

There were few studies showed that cases with large placental cysts with complex patterns inside the cyst. There may be an intracystic hematoma or intracystic hemorrhage.^[1,2] On the other hand, because of extensive use in prenatal sonography, many fetal neck masses were noted before delivery. Therefore,

Address for correspondence: Dr. Ching-Yu Chou,

Department of Obstetrics and Gynecology, Cathay General Hospital,
No. 678, Sec. 2, Zhonghua Rd., East Dist., Hsinchu City 300, Taiwan.
E-mail: chouchingyu@cgh.org.tw

Received: 29-12-2022 Revised: 26-01-2023 Accepted: 07-02-2023 Available Online: 06-04-2023

Access this article online

Quick Response Code:



Website:
<https://journals.lww.com/jmut>

DOI:
10.4103/jmu.jmu_123_22

This is an open access journal, and articles are distributed under the terms of the Creative Commons Attribution-NonCommercial-ShareAlike 4.0 License, which allows others to remix, tweak, and build upon the work non-commercially, as long as appropriate credit is given and the new creations are licensed under the identical terms.

For reprints contact: WKHLRPMedknow_reprints@wolterskluwer.com

How to cite this article: Chou CY, Lin LC. A placental cyst behind the fetal neck in the mid-trimester prenatal sonography may mimic a fetal cystic hygroma. J Med Ultrasound 2023;31:160-1.

accurate prenatal diagnosis of the fetal neck was essential for the parents. In our case, a posterior fetal neck mass was noted in the mid-trimester ultrasound examination. On ultrasound, these are clearly visible as multiple cysts with septations. The possible differential diagnosis includes cystic hygroma, cervical meningocele, occipital encephalocele, hemangioma, and lymphangioma.^[3] Among these diagnoses, cystic hygroma would show thickened skin. Further serial examination was particularly important for a prenatal diagnosis. An accurate diagnosis could decrease the anxiety of the parents and avoid unnecessary termination of pregnancy.

Ethical approval

The study was conducted in accordance with the Declaration of Helsinki and was approved by the Institutional Review Board of the Cathay General Hospital (CGH-P109073). Informed written consent was obtained from all patients prior to their enrollment in this study.

Financial support and sponsorship

Nil.

Conflicts of interest

Dr. Ching-Yu Chou, an editorial board member at *Journal of Medical Ultrasound*, had no role in the peer review process of or decision to publish this article. The other author declared no conflict of interest in writing this paper.

REFERENCES

1. Witters I, Sieprath P, Van Holsbeke C, Theyskens C, Deraedt K. Prenatal diagnosis of multiple large subchorionic placental cysts with intracystic hemorrhage. *Facts Views Vis Obgyn* 2017;9:223-5.
2. Hong SC, Yoo SW, Kim T, Yeom BW, Kim YT, Lee KW, *et al.* Prenatal diagnosis of a large subchorionic placental cyst with intracystic hematomas. A case report. *Fetal Diagn Ther* 2007;22:259-63.
3. Rauff S, Kien TE. Ultrasound diagnosis of fetal neck masses: A case series. *Case Rep Obstet Gynecol* 2013;2013:243590.